



A Diagnosis of Exclusion: A 3-Year-Old Boy With Respiratory Distress and Anemia

AUTHORS

Michael Joseph McCaffrey Cosimini, MD,¹
Kira Molas-Torreblanca, DO, FAAP,^{2,3} Roberta
M. Kato, MD,^{3,4} Shirleen Loloyan, MD,⁴ and
Anusha Ramanathan, MD,^{3,5}

¹*Pediatric Residency Program,*

²*Division of Hospital Medicine,*

³*Division of Pediatric Pulmonology, and*

⁴*Division of Pediatric Rheumatology, Department
of Pediatrics, Children's Hospital Los Angeles,
Los Angeles, California; and*

⁵*Keck School of Medicine, University of Southern
California, Los Angeles, California*

KEY WORDS

anemia, autoimmune disorders, pneumonia,
pulmonary

ABBREVIATIONS

AAV: antineutrophil cytoplasmic
antibody-associated vasculitides
ANCA: antineutrophil cytoplasmic antibody
BAL: bronchoalveolar lavage
CAP: community-acquired pneumonia
CRP: C-reactive protein
DAH: diffuse alveolar hemorrhage
ESR: erythrocyte sedimentation rate
IPH: idiopathic pulmonary hemosiderosis
PCR: polymerase chain reaction

www.hospitalpediatrics.org
doi:10.1542/hpeds.2013-0003

Address correspondence to Michael Joseph
McCaffrey Cosimini, MD, Children's Hospital
Los Angeles, 4650 Sunset Blvd, MS#68, Los
Angeles, CA 90027. E-mail: mcosimini@chla.
usc.edu

HOSPITAL PEDIATRICS (ISSN Numbers: Print,
2154 - 1663; Online, 2154 - 1671).

Copyright © 2013 by the American Academy
of Pediatrics

FINANCIAL DISCLOSURE: The authors have
indicated they have no financial relationships
relevant to this article to disclose.

FUNDING: No external funding.

POTENTIAL CONFLICT OF INTEREST: The
authors have indicated they have no potential
conflicts of interest to disclose.

Case: A 3-year-old boy presented to an outside hospital's emergency department with 3 days of worsening nonproductive cough. At the outside hospital, he was found to be hypoxic with a chest radiograph demonstrating bilateral infiltrates. He was transferred to our children's hospital with a presumed diagnosis of pneumonia.

On admission to our hospital, the patient was afebrile, pale, and in mild respiratory distress. Review of systems revealed low-grade fevers for 3 days before admission but no weight loss, vomiting, hemoptysis, or sick contacts. Medical history revealed a previous diagnosis of iron-deficiency anemia, which had resolved with ferrous sulfate administration. Family history was positive for asthma. Initial oxygen saturation was 88%, which recovered to 95% on 2 L/min of oxygen by nasal cannula. His heart rate was 138 beats per minute, and his respiratory rate was 44 breaths per minute; his blood pressure was 101/66 mm Hg. The patient's weight was 13.2 kg (10th–25th percentile), and his height was 91.5 cm (5th–10th percentile). On examination, pallor and subcostal and supraclavicular retractions were appreciated; auscultation of his lungs revealed slightly reduced breath sounds throughout, without wheeze or crackles. The rest of the physical examination was normal.

The patient was continued on oxygen by nasal cannula and was started on intravenous fluids for poor oral intake secondary to respiratory effort. He was also given ceftriaxone as treatment for presumed community-acquired pneumonia (CAP).

Question: *What further evaluation is indicated in the case of presumed pneumonia in a patient presenting with hypoxia and respiratory distress?*

Discussion: According to 2011 Infectious Diseases Society of America guidelines for CAP, posteroanterior and lateral chest radiographs should be obtained in all patients who are admitted for CAP to document infiltrates and to screen for complications of pneumonia, including parapneumonic effusion, necrotizing pneumonia, and pneumothorax.¹ The results of radiographs in CAP are variable and not predictive of the organism of infection. A prospective study of 150 pediatric patients hospitalized with CAP categorized the radiographic findings as: focal or segmental consolidation, with or without pleural effusion; atelectasis and consolidation indistinguishable from atelectasis; or interstitial pneumonia.² Focal or segmental consolidations were the most common category and were found in 75% of all cases of confirmed typical bacterial pathogens, 53% of all cases of confirmed atypical pneumonia, 45% of all viral pneumonia, and 69% of all mixed

bacterial/viral cases. Although focal infiltrate was not statistically predictive of a bacterial etiology, pleural effusions were found in 50% of typical bacterial cases and only 6% and 10% of atypical pathogens and viral pneumonias, which was a statistically significant difference.

Case Continuation: A chest radiograph was obtained on initial presentation, which revealed diffuse alveolar infiltrates that spared the apices and bases (Fig 1). In addition, a complete blood cell count was drawn on the basis of the medical history of anemia and the presence of pallor and tachycardia on examination. The significant complete blood cell count findings were: white blood cell count of $7.8 \times 10^3/\mu\text{L}$, hemoglobin of 6.2 g/dL, hematocrit of 21.8%, platelet count of $444 \times 10^3/\mu\text{L}$, mean corpuscular volume of 83.5 fL, and red cell distribution width of 20.2%. The differential showed 72.3% neutrophils, 22.2% lymphocytes, 5.2% monocytes, 0% eosinophils, and 0.3% basophils. Because of the anemia, a reticulocyte count was also performed

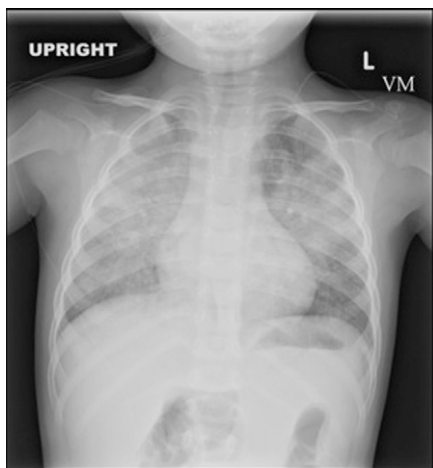


FIGURE 1 Chest radiograph on initial presentation. Confluent opacities are seen within the mid-lungs bilaterally, sparing the apices and bases.

and was elevated at 11.2%. Other iron study results included total iron-binding capacity of 466 $\mu\text{g}/\text{dL}$, ferritin of 8 ng/mL, and iron level of $<10 \mu\text{g}/\text{dL}$.

Treatment with ceftriaxone was continued. Azithromycin was added because *Mycoplasma pneumoniae* infection can cause diffuse infiltrates and hemolytic anemia.

Question: *Should M pneumoniae be considered in a 3-year-old with respiratory symptoms suggestive of pneumonia?*

Discussion: Although *M pneumoniae* is classically thought of as an infection of school-aged children, in a recent epidemiologic study of children admitted for respiratory infections, 18.1% of patients ages 1 to 3 years tested positive according to serology or polymerase chain reaction (PCR) for *M pneumoniae*.³

Case Continuation: Despite treatment with these 2 antibiotics, the patient remained hypoxemic and tachypneic. Given the lack of improvement on treatment, the anemia, and the abnormal chest radiograph, our pulmonary service was consulted and on hospital day 3, a bronchoscopy and a bronchoalveolar lavage (BAL) were performed.

Question: *What are the indications for bronchoscopy or BAL?*

Discussion: Bronchoscopy and BAL are not typically indicated in cases of pneumonia except: in cases of immunocompromised patients where opportunistic pathogens need to be identified; cases of chronic or recurrent pneumonias; or cases of severe pneumonia where initial diagnostic testing results are negative. In this case,

the bronchoscopy and BAL were performed because the chest radiograph, combined with the anemia and the elevated reticulocyte count (which can be a marker of acute bleeding), were concerning for alveolar hemorrhage. In cases of diffuse alveolar hemorrhage, chest radiograph findings are patchy or diffuse, often with apical and peripheral sparing.⁴ Cases with concern for alveolar hemorrhage require urgent guidance from a subspecialist and the ready availability of a higher level of care in case of rapid decomposition.

Case Continuation: Bronchoscopy showed diffuse bleeding from all lung segments originating from distal air spaces. BAL fluid was grossly bloody (Fig 2). Microscopically, BAL fluid was significant for hemosiderin-laden macrophages, which—along with anemia, hypoxemia, and a chest radiograph showing diffuse alveolar infiltrates—is consistent with a diagnosis of diffuse alveolar hemorrhage (DAH). DAH is a clinical syndrome resulting from damage to the alveolar capillary, arteriole, and venule that leads to red blood cell accumulation in the distal air space.⁵

Question: *In cases of suspected DAH, what further evaluation is indicated?*

DISCUSSION:

The differential diagnosis of DAH is broad. Autoimmune conditions

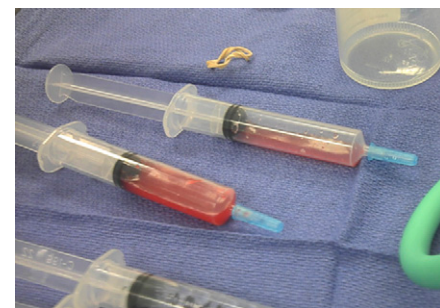

FIGURE 2 BAL fluid was grossly bloody.

are a common cause of DAH, most significantly the pulmonary-renal syndromes, including the antineutrophil cytoplasmic antibody (ANCA)-associated vasculitides (AAV). AAV include microscopic polyangiitis, eosinophilic granulomatosis with polyangiitis (Churg–Strauss syndrome), and granulomatosis with polyangiitis (formerly known as Wegener’s granulomatosis). To determine if the cause is autoimmune, initial evaluation beyond the history and physical examination should include urinalysis, urine protein to creatinine ratio, erythrocyte sedimentation rate (ESR), and testing for C-reactive protein (CRP), antimitochondrial antibodies (perinuclear ANCA), antiproteinase-3 antibodies (cytoplasmic ANCA), and antglomerular basement membrane (GBM) antibody. DAH can be a complication of systemic lupus erythematosus but is much less likely to be the presenting symptom.⁶ Other rheumatologic conditions such as mixed connective tissue disease, rheumatoid arthritis, dermatomyositis, and polymyositis are also less commonly associated with DAH.⁴ Primary antiphospholipid antibody syndrome is a known cause of DAH but is typically found in older male patients.⁷ ESR and CRP are both nonspecific studies that can produce elevated results in any of the aforementioned conditions; however, they tend to reach higher levels in AAV, systemic lupus erythematosus, and isolated pulmonary capillaritis than they do in idiopathic pulmonary hemosiderosis (IPH) and Goodpasture’s syndrome.⁸

Certain cardiac and vascular conditions have also been associated with DAH, including left-sided cardiac lesions, vascular malformations, and pulmonary hypertension.⁹ In addition, a number of infectious conditions,

as well as hematologic abnormalities, can lead to DAH. Drug-induced DAH and toxic inhalation must also be considered.

CASE CONTINUATION:

The patient was screened with urinalysis, urine protein to creatinine ratio, and for perinuclear ANCA, cytoplasmic ANCA, antglomerular basement membrane, and antinuclear antibody; the results of all tests were within reference ranges. Additional general screening for level of inflammation was performed, which showed a CRP level of 3.5 mg/dL. ESR was not measured. Imaging was done by using an echocardiogram and computed tomography of the chest, and the results revealed no signs of cardiac or vascular abnormalities. In this case, PCR of BAL fluid was done to look for respiratory viral pathogens and acid-fast bacilli. Bacterial and fungal cultures and stains were also performed. These studies were significant only for a positive PCR for rhinovirus. No laboratory evidence of thrombocytopenia or coagulopathy was found. Drug-induced DAH and toxic inhalation were excluded on the basis of history.

Given the negative results of these laboratory and radiologic studies, a presumed diagnosis of IPH was made.

Discussion: The etiology of IPH is unknown, and it is a diagnosis of exclusion when no other cause of DAH can be found. To fully exclude alternative diagnoses and to assess for capillaritis, a lung biopsy should be considered. Capillaritis on the biopsy results would suggest conditions calling for early aggressive treatment with immunosuppressive therapy. Because such associated conditions will not always be apparent on clinical and

laboratory data alone, in cases with negative serologic testing, the risk of the thoracoscopic biopsy and the associated complications must therefore be weighed against the use of long-term immunosuppression with an uncertain diagnosis.¹⁰ The need for biopsy is controversial, should be determined case-by-case, and would warrant subspecialty consultation. In addition, the timing of the biopsy must be considered, as immunosuppression may alter the pathologic findings on the biopsy.

The pulmonary hemorrhage in IPH, as well as other immune-mediated causes of DAH, is life-threatening and warrants prompt initiation of steroid therapy. IPH must be treated both at the acute presentation as well as on an ongoing basis as symptoms recur. Recurrence can present either with a chronic low level of bleeding or acute hemorrhage. Although use of steroids is standard for acute management, it is desirable to use other medications to control symptoms on a longer term basis to avoid the adverse effects of steroids. A variety of other immunomodulatory medications have been used in the treatment of IPH, including azathioprine, hydroxychloroquine, cyclophosphamide, and methotrexate.¹¹ Comparable efficacy is not well known.

Although data are limited, there are variable reports of the prognosis of IPH. A survival rate of 86% at 5 years postdiagnosis was reported in a study of 17 patients treated with steroids as well as immunomodulatory medications.¹² A study in 1962 reviewed 68 patients who were diagnosed while living and reported that 30% of those died at an average of 3.3 years after diagnosis.¹³ This study was done

when treatment consisted of steroids, splenectomy, and adrenocorticotropic hormone. Early recognition and non-steroidal immunomodulatory medication may contribute to the dramatic improvement in outcomes.

In addition to treatment, long-term screening for onset of pulmonary-renal conditions and AAV are warranted because these test results may initially be negative but become positive on follow-up as much as 3 years later.¹⁴ Because treatment of IPH differs from the treatments for both pulmonary-renal vasculitides and AAV, careful consideration of an alternative diagnosis should be ongoing.

Case Resolution: As soon as the presumptive diagnosis of IPH was made, treatment was initiated with 1 mg/kg of methylprednisolone every 6 hours, which led to improvement of the patient's tachypnea and hypoxemia. Markers of the level of active bleeding improved, along with decreasing reticulocyte count and stabilization of the patient's hemoglobin level. Resolution of infiltrates was documented with serial radiographs. With this treatment, the patient was weaned off of oxygen and was transitioned to oral prednisone and azathioprine (as a steroid-sparing agent) with a planned prednisone taper.

In this case, a biopsy was desired; however, the patient was not clinically stable for biopsy on presentation and has been on immunosuppressive medication since his diagnosis. Almost 1 year later, our patient is doing well with no further hospitalizations. He is managed as an outpatient with azathioprine treatment and is tolerating a tapering off of oral steroids.

LEARNING POINTS:

- All patients admitted to the hospital for presumed community-acquired pneumonia should have a chest radiograph to document infiltrates and to screen for complications of pneumonia.
- The radiographic findings of diffuse alveolar hemorrhage (DAH) are alveolar in appearance and patchy or diffuse, often with apical and peripheral sparing.
- In cases of DAH, prompt referral for subspecialist care and initiation of steroids can prevent life-threatening hemorrhage.
- Idiopathic pulmonary hemosiderosis is a diagnosis of exclusion when no other cause of DAH can be found.
- The reticulocyte count is a sensitive measure for hemorrhage, both in detecting suspected cases of hemorrhage and in monitoring response to therapy.

REFERENCES

1. Bradley JS, Byington CL, Shah SS, et al; Pediatric Infectious Diseases Society and the Infectious Diseases Society of America. Executive summary: the management of community-acquired pneumonia in infants and children older than 3 months of age: clinical practice guidelines by the Pediatric Infectious Diseases Society and the Infectious Diseases Society of America. *Clin Infect Dis*. 2011;53(7):617-630.
2. Michelow IC, Olsen K, Lozano J, et al. Epidemiology and clinical characteristics of community-acquired pneumonia in hospitalized children. *Pediatrics*. 2004;113(4):701-707.
3. He XY, Wang XB, Zhang R, et al. Investigation of *Mycoplasma pneumoniae* infection

in pediatric population from 12,025 cases with respiratory infection. *Diagn Microbiol Infect Dis*. 2013;75(1):22-27.

4. Lara AR, Schwarz MI. Diffuse alveolar hemorrhage. *Chest*. 2010;137(5):1164-1171.
5. Olson AL, Schwarz MI. Diffuse alveolar hemorrhage. In: Costabel U, du Bois RM, Egan JJ, eds. *Diffuse Parenchymal Lung Disease*. Vol. 36, Progress in Respiratory Research. Basel, Switzerland: Karger; 2007:250-263.
6. Vijatov-Djuric G, Stojanovic V, Tomic J, Konstantinidis N, Konstantinidis G. Systemic lupus erythematosus complicated with pulmonary hemorrhage in a 17-year-old female. *Lupus*. 2010;19(13):1561-1564.
7. Deane KD, West SG. Antiphospholipid antibodies as a cause of pulmonary capillaritis and diffuse alveolar hemorrhage: a case series and literature review. *Semin Arthritis Rheum*. 2005;35(3):154-165.
8. Vece TJ, Guzman MM, Langston C, Fan LL. Diffuse alveolar hemorrhage in Children In: Vogelstein B, Kinzler KW, eds. *Kendig and Chernick's Disorders of the Respiratory Tract in Children*. 8th ed. Philadelphia, PA: Elsevier; 2012:857.
9. Susarla SC, Fan LL. Diffuse alveolar hemorrhage syndromes in children. *Curr Opin Pediatr*. 2007;19(3):314-320.
10. Fullmer JJ, Langston C, Dishop MK, Fan LL. Pulmonary capillaritis in children: a review of eight cases with comparison to other alveolar hemorrhage syndromes. *J Pediatr*. 2005;146(3):376-381.
11. Ioachimescu OC, Sieber S, Kotch A. Idiopathic pulmonary haemosiderosis revisited. *Eur Respir J*. 2004;24(1):162-170.
12. Saeed MM, Woo MS, MacLaughlin EF, Margetis MF, Keens TG. Prognosis in pediatric idiopathic pulmonary hemosiderosis. *Chest*. 1999;116(3):721-725.
13. Soergel KH, Sommers SC. Idiopathic pulmonary hemosiderosis and related syndromes. *Am J Med*. 1962;32:499-511.
14. Baird EM, Lehman TJ, Worgall S. Combination therapy with rituximab and cyclophosphamide in the treatment of anti-neutrophil cytoplasmic antibodies (ANCA) positive pulmonary hemorrhage: case report. *Pediatr Rheumatol Online J*. 2011;9:33.

A Diagnosis of Exclusion: A 3-Year-Old Boy With Respiratory Distress and Anemia

Michael Joseph McCaffrey Cosimini, Kira Molas-Torreblanca, Roberta M. Kato, Shirleen Loloyan and Anusha Ramanathan

Hospital Pediatrics 2013;3;377

DOI: 10.1542/hpeds.2013-0003

Updated Information & Services	including high resolution figures, can be found at: http://hosppeds.aappublications.org/content/3/4/377
References	This article cites 12 articles, 2 of which you can access for free at: http://hosppeds.aappublications.org/content/3/4/377.full#ref-list-1
Subspecialty Collections	This article, along with others on similar topics, appears in the following collection(s): Blood Disorders http://classic.hosppeds.aappublications.org/cgi/collection/blood_disorders_sub Hematology/Oncology http://classic.hosppeds.aappublications.org/cgi/collection/hematology:oncology_sub Pulmonology http://classic.hosppeds.aappublications.org/cgi/collection/pulmonology_sub
Permissions & Licensing	Information about reproducing this article in parts (figures, tables) or in its entirety can be found online at: https://shop.aap.org/licensing-permissions/
Reprints	Information about ordering reprints can be found online: http://classic.hosppeds.aappublications.org/content/reprints

A Diagnosis of Exclusion: A 3-Year-Old Boy With Respiratory Distress and Anemia

Michael Joseph McCaffrey Cosimini, Kira Molas-Torreblanca, Roberta M. Kato,
Shirleen Loloan and Anusha Ramanathan

Hospital Pediatrics 2013;3;377

DOI: 10.1542/hpeds.2013-0003

The online version of this article, along with updated information and services, is
located on the World Wide Web at:

<http://hosppeds.aappublications.org/content/3/4/377>

Hospital Pediatrics is the official journal of the American Academy of Pediatrics. A monthly publication, it has been published continuously since 2012. Hospital Pediatrics is owned, published, and trademarked by the American Academy of Pediatrics, 345 Park Avenue, Itasca, Illinois, 60143. Copyright © 2013 by the American Academy of Pediatrics. All rights reserved. Print ISSN: 2154-1663.

American Academy of Pediatrics

DEDICATED TO THE HEALTH OF ALL CHILDREN™

