



# Nothing Is Simple About a Complex Febrile Seizure: Looking Beyond Fever as a Cause for Seizures in Children

## AUTHORS

Sheila M. Hofert, MD,<sup>1,2</sup> Michael G. Burke, MD<sup>1,2</sup>

<sup>1</sup>Department of Pediatrics, St Agnes Hospital, Baltimore, Maryland; and

<sup>2</sup>Department of Pediatrics, Johns Hopkins University School of Medicine, Baltimore, Maryland

## KEY WORDS

complex febrile seizures, simple febrile seizures, epilepsy, infectious disease, herpes simplex virus

## ABBREVIATIONS

CFS: complex febrile seizure  
 CNS: central nervous system  
 CSF: cerebral spinal fluid  
 CT: computed tomography  
 EEG: electroencephalogram  
 FLAIR: fluid-attenuated inversion recovery  
 FSE: febrile status epilepticus  
 HSE: herpes simplex encephalitis  
 HSV: herpes simplex virus  
 IV: intravenous  
 MRI: magnetic resonance imaging  
 PCR: polymerase chain reaction  
 RBC: red blood cell  
 SFS: simple febrile seizure

www.hospitalpediatrics.org  
 doi:10.1542/hpeds.2013-0098

Address correspondence to Sheila M. Hofert, MD, Department of Pediatrics, St Agnes Hospital, 900 Caton Ave, Baltimore, MD 21229. E-mail: shofert1@jhmi.edu

HOSPITAL PEDIATRICS (ISSN Numbers: Print, 2154 - 1663; Online, 2154 - 1671).

Copyright © 2014 by the American Academy of Pediatrics

**FINANCIAL DISCLOSURE:** The authors have indicated they have no financial relationships relevant to this article to disclose.

**FUNDING:** No external funding.

**POTENTIAL CONFLICT OF INTEREST:** The authors have indicated they have no potential conflicts of interest to disclose.

**Case:** A 16-month-old, previously healthy girl presented with fever for 2 days. Other symptoms included rhinorrhea, cough, decreased activity, and oral ulcerations associated with decreased oral intake. The child had no vomiting, diarrhea, rashes, head trauma or other injuries. There were no sick contacts. The child's father denied home medications and ingestions. Immunizations were up to date and included her first influenza vaccine.

In triage the child had a temperature of 39.8°C, pulse of 164 beats per minute, respiratory rate of 20 breaths per minute, and oxygen saturation of 98%. She appeared tired and irritable but was consolable. She was given ibuprofen (10 mg/kg/dose). As the child was placed in the examination room, she became unresponsive with rightward eye deviation, drooling, and symmetric tonic-clonic seizure activity. The seizure continued for >10 minutes despite rectal diazepam (0.1 mg/kg/dose) and concluded after intravenous midazolam (0.1 mg/kg/dose). She was also given acetaminophen (15 mg/kg/dose per rectum). A 20-minute postictal period was followed by a second 10-minute seizure, which required intravenous (IV) midazolam (0.1mg/kg/dose) and a load of IV fosphenytoin (20 mg/kg/dose).

**Question:** *What are current recommendations for the evaluation and management of a child with a complex febrile seizure (CFS)?*

**Discussion:** Recent guidelines on management of simple febrile seizures (SFS) offer support for clinicians caring for children with this condition.<sup>1</sup> However, similar consensus and guidance is harder to find for management of CFS in pediatrics. Febrile seizures affect 2% to 5% of children, usually aged between 6 months and 5 years.<sup>2</sup> From 25% to 30% of febrile seizures are classified as CFS,<sup>2,3</sup> defined as a those seizures associated with fever and with any of the following characteristics: duration >15 minutes, recurrence within 24 hours, focality, and/or associated neurologic abnormalities.<sup>4</sup> A meta-analysis by Offringa et al<sup>5</sup> showed that the following criteria increase the risk of a CFS: age <12 months, history of unprovoked seizures in first-degree relatives, and a focal initial febrile seizure. Additionally, the risk of a future unprovoked seizure after a simple febrile seizure is 2.5%; only slightly higher than the 1.4% risk of unprovoked seizures in the general population of 2- to 25-year-olds. In contrast, the risk of future unprovoked seizures in a patient with a CFS is higher: 6% to 8% with 1 feature of CFS, 17% to 20% with 2 features (eg, prolonged and focal), and 49% with 3 features.<sup>6</sup>

In 2008, an American Academy of Pediatrics practice guideline advised against the use of intermittent or continuous anticonvulsant medication for children with

SFS.<sup>7</sup> In additional recommendations from 2011, the Academy further suggested that, in general, an SFS does not require diagnostic evaluation for other than the source of the fever.<sup>1</sup> A lumbar puncture is an option in children with SFS who are between the ages of 6 and 12 months and for those who are underimmunized or on antimicrobial therapy at the time of presentation.<sup>1</sup> Further evaluation, specifically electroencephalography (EEG); blood studies such as serum electrolytes, calcium, phosphorus, magnesium, blood glucose, or a complete blood cell count; or neuroimaging, is not recommended.<sup>1</sup>

Because CFSs are more likely to recur and particularly because they are more likely than SFS to have a harmful etiology, potentially requiring immediate treatment, physicians treating a child with a CFS are more likely to pursue a thorough diagnostic evaluation. Although guidelines for management of SFS are available, similar guidelines for CFS are more difficult to find. This has resulted in wide variability in care of children with this condition. In a recent survey of 353 emergency physicians in 10 U.S. hospitals asked about management of patients with CFS, 54% indicated that they would obtain blood tests, 62% indicated they would obtain urine, 34% indicated that they would perform a lumbar puncture, and 36% would perform neuroimaging.<sup>8</sup>

**Case continuation:** Following treatment with anticonvulsants for persistent seizures, the patient's neurologic status failed to improve to baseline. The child was intubated for a Glasgow Coma Scale score of 7 and was transferred to a PICU.

**Question:** *When are neuroimaging, laboratory studies, lumbar puncture, and EEGs indicated in children with CFS?*

**Discussion:** Despite the fact that 36% of physicians in the emergency medicine survey obtained neuroimaging in patients with CFS, earlier studies have shown that, in the absence of a history of trauma or signs and symptoms of increased intracranial pressure, routine neuroimaging in children with CFS is of low yield.<sup>9-13</sup>

These findings were confirmed in a more recent study from Children's Hospital of Boston in which the authors sought to assess the risk of intracranial pathology requiring immediate intervention among children presenting with their first CFS.<sup>14</sup> In a 7-year retrospective cohort study, medical records of 526 patients, aged 6 to 60 months, who were otherwise healthy but presenting with CFS to this urban tertiary care pediatric emergency department were reviewed. Patients were excluded from evaluation if their seizures concluded within 15 minutes with IV or rectal benzodiazepine administration. Of the 526 patients reviewed, 268 underwent computed tomography (CT), 6 underwent magnetic resonance imaging (MRI), and 8 patients had both. Four of 268 patients had significant findings (2 intracranial bleeds, 1 acute disseminated encephalomyelitis, and 1 with cerebellar abnormalities). In a 6-month follow-up, none of those patients who avoided neuroimaging returned with later central nervous system (CNS) findings.<sup>14</sup> In this and other studies, the largest percentage of CFS patients was the group of children who experienced 2 seizures in 24 hours.<sup>4,14</sup> None of the 4 children with CNS abnormalities in

this study had a CFS based on recurrence of seizures within 24 hours.<sup>14</sup> In a separate retrospective chart review of 45 patients who had neuroimaging after a first CFS, 7 (16%) had abnormal findings, but none required emergent intervention.<sup>15</sup> Based on these studies, emergent neuroimaging for well-appearing patients with a normal neurologic examination after a CFS is not recommended, especially in those children meeting criteria solely by having a second seizure within 24 hours.

There is also lack of consensus on the necessity of laboratory testing in children with CFS.<sup>9</sup> The reason for the lack of consensus may be based on the wide variability in the patients with CFS. A child with a CFS who is well appearing and has had 2 brief seizures in 24 hours may have a similar prognosis as a child with SFS, whereas a child who fails to return to his or her neurologic baseline after a CFS may warrant a different evaluation. There is compelling evidence that routine measurement of electrolytes or glucose is not required in SFS.<sup>16</sup> However, in a child with febrile status epilepticus (FSE), defined as seizures or series of seizures that last  $\geq 30$  minutes without recovery of normal mental status, evaluation for hypoglycemia, and other electrolyte abnormalities is indicated. Similarly, a child with FSE or one who is obtunded after a self-limited seizure may be at risk for toxic ingestion. Therefore, in the case of CFS, clinical judgment based on variable presentations must direct the laboratory testing. Testing may include a complete blood count, blood culture, electrolytes, glucose, and a toxicology screen.

Concern for bacterial meningitis as a cause for CFS has long precipitated lumbar puncture as part of this

evaluation.<sup>17</sup> Decreasing prevalence of bacterial meningitis and more recent evidence that CFS alone is a rare presentation for bacterial meningitis have now brought this practice into question. In a study by Green et al of 111 children with bacterial meningitis who presented with seizures, 103 were classified as obtunded or comatose at presentation. The remaining 8 children all had some other clinical finding, including an abnormal neurologic examination or nuchal rigidity, to indicate meningitis.<sup>18</sup>

Other researchers have reached similar conclusions. Kimia et al reported that of 337 children who underwent lumbar puncture after CFS, 3 had bacterial meningitis.<sup>19</sup> Two with *Streptococcus pneumoniae* meningitis had significant changes in mental status in addition to CFS. A third child had a positive blood culture but was well appearing and had no growth on a culture of bloody cerebral spinal fluid (CSF). Teach and Geil reported that of the 243 children with febrile seizures (89% simple and 11% complex), none had acute bacterial meningitis.<sup>20</sup> Also, Seltz et al, in a retrospective chart review of 390 patients with CFS, found 6 cases of meningitis and 1 case of herpes simplex virus (HSV) encephalitis (HSE). All of these patients had altered mental status on presentation.<sup>21</sup> Patients with FSE may present an exception.<sup>22</sup> Chin et al in a prospective population-based study, reported that as many as 17% of children with FSE were found to have acute bacterial meningitis.<sup>22</sup> Therefore, a lumbar puncture should be reserved for children aged <12 months, febrile status epilepticus, prolonged change in mental status, nuchal rigidity, or focal neurologic signs and symptoms.

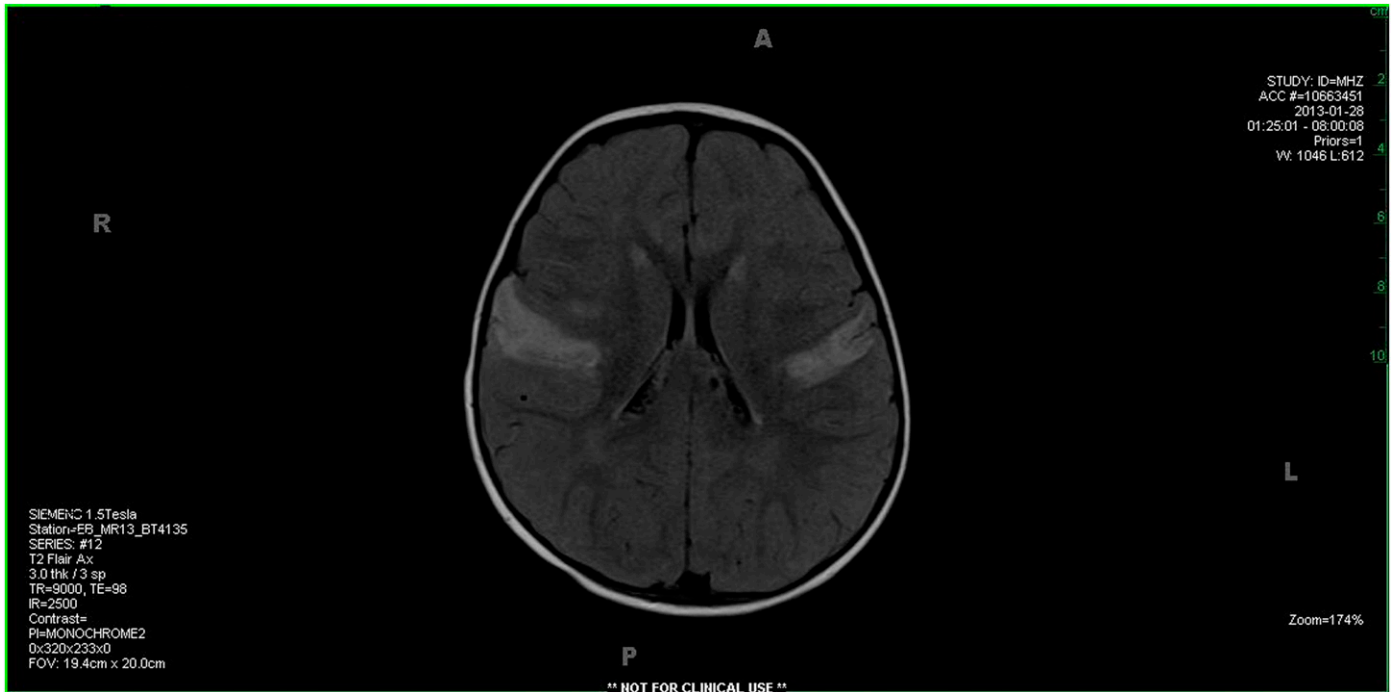
Several studies have called into question the utility of an EEG in children with CFS.<sup>23,24</sup> However, EEG may be used as a means of establishing prognosis for development of epilepsy. The National Institute of Neurologic and Communicative Disorders and Stroke Collaborative Perinatal Project has shown that patients who present with CFS and who have both a family history of nonfebrile seizures and a personal history of a preexisting neurologic abnormality have a 10% risk of developing epilepsy.<sup>4</sup> Additionally, children with CFS alone have a fivefold increase risk of developing epilepsy compared with the general population.<sup>25</sup> That risk is increased incrementally in children with >1 of the defining characteristics of CFS (duration, focality, recurrence, lasting change in neurologic status).<sup>6</sup> Delaying the EEG until  $\geq 7$  days after the seizure activity will decrease false-positive results due to generalized slowing caused by the seizures.<sup>26</sup> Therefore, an outpatient EEG is indicated in patients with abnormal neurodevelopment, family history of epilepsy, or >1 feature of CFS. This conclusion was also supported by a recent review by Patel et al.<sup>27</sup>

**Case continuation:** A head CT was positive for areas of hyperattenuation, likely representing blood but non-specific; therefore, additional studies, including an MRI and a lumbar puncture, were obtained. The MRI (Fig 1) showed restricted diffusivity within the bilateral posterior frontal and anterior parietal lobes, consistent with viral encephalitides with tropism for these regions of the brain. Sparing of the basal ganglia decreased the likelihood of a toxic/metabolic insult. Additionally, a vascular etiology was less likely due to the symmetry and normal appearance of the vessels in

the magnetic resonance angiography/venography. The lumbar puncture showed 25 white blood cells and 32700 red blood cells (RBCs) per high-powered field. CSF was subsequently positive for HSV polymerase chain reaction (PCR), with later serologic confirmation for HSV-1. MRI findings, along with the positive HSV PCR, were consistent with the diagnosis of HSE. The patient was initially treated with IV ceftriaxone (100 mg/kg/dose), vancomycin (15 mg/kg/dose), and acyclovir (20 mg/kg/dose), but later the antibiotics were discontinued, and the patient completed a 21-day course of intravenous acyclovir (20 mg/kg/dose, 3 times a day). The child's seizures recurred and proved difficult to treat. She was discharged to a chronic care facility after a 9-day hospital stay. At the time of discharge, she had significant neurologic impairment but was continuing to make slow progress in physical and occupational therapy.

**Question:** *Which patients with CFS should be worked up for the possibility of HSE?*

**Discussion:** HSE is a rare cause of CFS in children. In an investigation of 390 children with CFS, Seltz et al found that 0.3% had HSE.<sup>21</sup> Both HSV-1 and HSV-2 infections have been implicated with CNS disease. However, HSE is caused by HSV-1 infections in 93% to 96% of cases.<sup>28</sup> There may be a difference in neurologic manifestations and pathways of transmission to the CNS for these 2 types of HSV infections. The majority of patients with CNS disease with HSV-2 develop meningitis, with newborns and adults comprising the typical patient population. In contrast, patients with HSV-1 CNS infection are primarily children and develop HSE rather than meningitis.<sup>29</sup> Spread



**FIGURE 1** T2-FLAIR axial image showing restricted diffusion with hyperintense signal in anterior parietal gyri.

of HSV-1 to the CNS proceeds by 3 possible pathways; neurogenic, hematogenous dissemination, or spread through the nasopharyngeal mucosa into the cribriform plate. In patients with HSV-2 meningitis, there usually is no involvement of the brain itself, and it is possible that the infection is spread either through neuronal pathways or hematogenous spread.<sup>30</sup>

Of all patients with childhood encephalitis, 2% to 5% have historically been associated with HSV.<sup>31</sup> The incidence of childhood encephalitis has been reported as 30 per 100 000 (study between 1950 and 1981).<sup>32</sup> However, a study by Koskiniemi et al showed an overall incidence of childhood encephalitis of 10.5 per 100 000 children during a 2-year surveillance period (1993–1994), of which ~5% was attributed to HSE.<sup>33</sup> In a more recent 12-year prospective study, Elbers et al also found that HSV accounted for 5% of all cases of acute childhood

encephalitis.<sup>34</sup> Therefore, the relative incidence of HSE may have increased compared with the total incidence of the childhood encephalitis. This is most likely due to widespread vaccination for other viruses such as mumps, measles, and rubella, all of which historically contributed to the incidence of childhood encephalitis.

Diagnosis of HSE cannot be made through clinical findings because they are nonspecific. Children can present with fever, malaise, fussiness, decrease oral intake, and eventually irritability, lethargy, or other neurologic abnormalities. The most common findings in patients with HSE are altered mental status, fever, and seizures.<sup>31</sup> Laboratory diagnosis is also not based on a single test. CSF findings include pleocytosis with a predominance of lymphocytes, which will be present in most of the cases. Currently, the most accurate test is an HSV PCR of the CSF, which is 98% sensitive

and 94% specific.<sup>35</sup> These figures were obtained from several National Institute of Allergy and Infectious Disease Collaborative Antiviral Study Group therapeutic studies of HSE in both adult and pediatric patients.<sup>35</sup>

These test characteristics may vary in populations of children alone. In a 12-year prospective study of childhood HSE, Elbers et al reported that in a population of 322 children with encephalitis, 16 children had serologically confirmed HSV disease, of whom only 12 (75%) had positive CSF HSV PCRs.<sup>34</sup> Additionally, 17% ( $n=2$ ), of the patients with positive PCRs had negative PCRs on day 1 and subsequently positive results on days 3 and 7. De Tiege et al reviewed 38 cases of children with HSE and found that eight of 33 had initial negative CSF HSV PCR results.<sup>36</sup> False-negative HSV PCRs most often occur early in the course of the infection.<sup>34,37</sup> Researchers hypothesize that early in the course of HSE, the virus



may be present in brain tissue before spreading to the CSF and meninges. This hypothesis is supported by lack of CSF pleocytosis in some children with HSE as well as negative early CSF HSV PCR.<sup>37</sup> Additionally, there may be a correlation between the location of brain involvement and CSF HSV PCR false negatives in children. De Tiege et al reported a case of a child with PCR-negative HSE involving the left parietal lobe and left thalamus rather than the typical temporal lobe location.<sup>38</sup> In the study of 38 children with HSE mentioned earlier, 40% had frontal, parietal, or occipital lesions. This group had a disproportionately high rate of negative-HSV PCR at diagnosis. This may suggest a different path of HSV access to the CNS in younger patients.<sup>38</sup>

The finding of CSF RBCs is also inconsistent in children with HSE. In more than half of cases, there are RBCs in the CSF, which is consistent with intracranial hemorrhage.<sup>39</sup> Patients with CSF RBCs may have a worse prognosis.<sup>40</sup> HSV viral cultures are often negative from the CSF. Surface cultures are also of mixed utility because they are not sensitive, and results take up to 5 to 7 days.

In suspected HSV as a cause for CFS, neuroimaging may be useful. In the acute setting, when MRI is not available, a CT scan may show hemorrhagic brain necrosis, appearing as low-density lesions and causing localized mass effect.<sup>41</sup> However, especially early in the course of disease and in the absence of hemorrhagic necrosis, a negative CT scan has poor negative predictive value.<sup>42</sup> Elbers et al reported that in patients with HSE who had normal CT studies followed by MRI, 67% of MRI studies

showed significant abnormalities.<sup>34</sup> Additionally, Greenberg et al showed that 5 patients with brain biopsy-proven HSE had normal CT scans 1 to 7 days after the onset of illness.<sup>43</sup> MRI is more sensitive in detecting brain lesions and should be used if it is available as the first diagnostic step after clinical assessment.<sup>42,44</sup> However, even a negative MRI should not stop the clinician from performing further workup of a patient in whom HSE is suspected because associated morbidity and mortality are significant, and as many as 12% of patients with confirmed HSE have normal MRI neuroimaging.<sup>34,45</sup>

Figure 1 is the T2 fluid-attenuated inversion recovery (FLAIR) axial image of this patient's brain MRI. The hyperintense signal changes and diffusion limitation especially observed in T2-FLAIR sequences are typical for changes seen in the brain of patients with HSE.<sup>46</sup>

In any patient in whom there is strong clinical suspicion of HSE, it is critical to ensure early treatment with acyclovir even in a setting of a normal CSF cell count, negative HSV PCR, negative or pending herpes cultures, and negative imaging studies. The recommended dose of acyclovir for children aged 3 months to 12 years is 20 mg/kg/dose administered IV every 8 hours. The dose is adjusted to 10 mg/kg/dose for children >12 years of age.<sup>47</sup> The recommended duration of therapy is 21 days, a duration that has been shown to be associated with a decrease in adverse neurologic outcomes and decreased relapse of symptoms compared with a 14-day course.<sup>34</sup>

Without therapy HSE has a 70% mortality rate.<sup>48</sup> Even with acyclovir therapy, the mortality rate at 6 months is

19%.<sup>49</sup> Prompt treatment and longer course therapy have been associated with better long-term neurologic function.<sup>34,48</sup>

**Conclusions:** CFS comprises a heterogeneous group of processes, and 1 set of guidelines may not be applicable to all patients. For patients with 2 self-limited febrile seizures in 24 hours but a return to normal neurologic status, it may be appropriate to avoid any additional workup, treating these children similarly to those with SFS. A more aggressive approach is warranted for children with other forms of CFS, including those with status epilepticus, altered mental status, focal seizures, or focal neurologic symptoms. Additionally, abnormal physical examination findings including nuchal rigidity and a bulging fontanel, increase the risk of a more serious condition. For these children, a lumbar puncture, other laboratory tests, and imaging may be necessary in the acute visit. EEG is not usually recommended in the acute setting because there may be false positives. Children with >1 feature of CFS (eg, prolonged and focal), abnormal neurodevelopment, and a family history of epilepsy are indicated for follow-up with a neurologist and an outpatient EEG because there is a fivefold increase in subsequent unprovoked seizures in these children.

In the patient described here, a workup including lumbar puncture and imaging was necessary because she had many worrisome features, including status epilepticus, focal seizures, a change in mental status, and an abnormal neurologic examination. A high index of suspicion for HSE should be maintained in patients with CFS and altered mental status or abnormal imaging consistent with hemorrhagic

necrosis to ensure quick initiation of adequate and appropriate treatment.

## REFERENCES

- Subcommittee on Febrile Seizures, American Academy of Pediatrics. Neurodiagnostic evaluation of the child with a simple febrile seizure. *Pediatrics*. 2011;127(2):389–394.
- Waruiru C, Appleton R. Febrile seizures: an update. *Arch Dis Child*. 2004;89(8):751–756.
- Berg AT, Shinnar S. Complex febrile seizures. *Epilepsia*. 1996;37(2):126–133.
- Nelson KB, Ellenberg JH. Prognosis in children with febrile seizures. *Pediatrics*. 1978;61(5):720–727.
- Offringa M, Bossuyt PM, Lubsen J, et al. Risk factors for seizure recurrence in children with febrile seizures: a pooled analysis of individual patient data from five studies. *J Pediatr*. 1994;124(4):574–584.
- Annegers JF, Hauser WA, Shirts SB, Kurland LT. Factors prognostic of unprovoked seizures after febrile convulsions. *N Engl J Med*. 1987;316(9):493–498.
- Steering Committee on Quality Improvement and Management, Subcommittee on Febrile Seizures American Academy of Pediatrics. Febrile seizures: clinical practice guideline for the long-term management of the child with simple febrile seizures. *Pediatrics*. 2008;121(6):1281–1286 10.1542/pes.2008-0939.
- Sales JW, Bulloch B, Hostetler MA. Practice variability in the management of complex febrile seizures by pediatric emergency physicians and fellows. *CJEM*. 2011;13(3):145–149.
- Al-Qudah AA. Value of brain CT scan in children with febrile convulsions. *J Neurosci*. 1995;128:107–110.
- Teng D, Dayan P, Tyler S, et al. Risk of intracranial pathologic conditions requiring emergency intervention after a first complex febrile seizure episode among children. *Pediatrics*. 2006;117(2):304–308.
- Garvey MA, Gaillard WD, Rusin JA, et al. Emergency brain computed tomography in children with seizures: who is most likely to benefit? *J Pediatr*. 1998;133(5):664–669.
- Maytal J, Krauss JM, Novak G, Nagelberg J, Patel M. The role of brain computed tomography in evaluating children with new onset of seizures in the emergency department. *Epilepsia*. 2000;41(8):950–954.
- Warden CR, Zibulewsky J, Mace S, Gold C, Gausche-Hill M. Evaluation and management of febrile seizures in the out-of-hospital and emergency department settings. *Ann Emerg Med*. 2003;41(2):215–222.
- Kimia AA, Ben-Joseph E, Prabhu S, et al. Yield of emergent neuroimaging among children presenting with a first complex febrile seizure. *Pediatr Emerg Care*. 2012;28(4):316–321.
- Yücel O, Aka S, Yazicioglu L, Ceran O. Role of early EEG and neuroimaging in determination of prognosis in children with complex febrile seizure. *Pediatr Int*. 2004;46(4):463–467.
- Jaffe M, Bar-Joseph G, Tirosh E. Fever and convulsions—indications for laboratory investigations. *Pediatrics*. 1981;67(5):729–731.
- Joffe A, McCormick M, DeAngelis C. Which children with febrile seizures need lumbar puncture? A decision analysis approach. *Am J Dis Child*. 1983;137(12):1153–1156.
- Green SM, Rothrock SG, Clem KJ, Zurcher RF, Mellick L. Can seizures be the sole manifestation of meningitis in febrile children? *Pediatrics*. 1993;92(4):527–534.
- Kimia A, Ben-Joseph EP, Rudloe T, et al. Yield of lumbar puncture among children who present with their first complex febrile seizure. *Pediatrics*. 2010;126(1):62–69.
- Teach SJ, Geil PA. Incidence of bacteremia, urinary tract infections, and unsuspected bacterial meningitis in children with febrile seizures. *Pediatr Emerg Care*. 1999;15(1):9–12.
- Seltz LB, Cohen E, Weinstein M. Risk of bacterial or herpes simplex virus meningitis/encephalitis in children with complex febrile seizures. *Pediatr Emerg Care*. 2009;25(8):494–497.
- Chin RF, Neville BG, Scott RC. Meningitis is a common cause of convulsive status epilepticus with fever. *Arch Dis Child*. 2005;90(1):66–69.
- Maytal J, Steele R, Eviatar L, Novak G. The value of early postictal EEG in children with complex febrile seizures. *Epilepsia*. 2000;41(2):219–221.
- Kuturec M, Emoto SE, Sofijanov N, et al. Febrile seizures: is the EEG a useful predictor of recurrences? *Clin Pediatr (Phila)*. 1997;36(1):31–36.
- Hamati-Haddad A, Abou-Khalil B. Epilepsy diagnosis and localization in patients with antecedent childhood febrile convulsions. *Neurology*. 1998;50(4):917–922.
- Nordli DR, Moshé SL, Shinnar S. The role of EEG in febrile status epilepticus (FSE). *Brain Dev*. 2010;32(1):37–41.
- Patel AD, Vidaurre J. Complex febrile seizures: a practical guide to evaluation and treatment. *J Child Neurol*. 2013;28(6):762–767.
- Aurelius E, Johansson B, Sköldenberg B, Forsgren M. Encephalitis in immunocompetent patients due to herpes simplex virus type 1 or 2 as determined by type-specific polymerase chain reaction and antibody assays of cerebrospinal fluid. *J Med Virol*. 1993;39(3):179–186.
- Craige C, Nabmias AJ. Different patterns of neurologic involvement with herpes simplex virus type 1 and 2: isolation of herpes simplex virus type 2 from the buffy coat of two adults with meningitis. *J Infect Dis*. 1973;127(4):365–372.
- Jones C, Britton P. Central nervous system herpesvirus infections. *Pediatr Child Health*. In press.
- Rantala H, Uhari M. Occurrence of childhood encephalitis: a population-based study. *Pediatr Infect Dis J*. 1989;8(7):426–430.
- Beghi E, Nicolosi A, Kurland LT, Mulder DW, Hauser WA, Shuster L. Encephalitis and aseptic meningitis, Olmsted County, Minnesota, 1950–1981: I. Epidemiology. *Ann Neurol*. 1984;16(3):283–294.
- Koskineniemi M, Korppi M, Mustonen K, et al. Epidemiology of encephalitis in children. A prospective multicentre study. *Eur J Pediatr*. 1997;156(7):541–545.
- Elbers JM, Bitnun A, Richardson SE, et al. A 12-year prospective study of childhood herpes simplex encephalitis: is there a broader spectrum of disease? *Pediatrics*. 2007;119(2):e399–e407.
- Lakeman FD, Whitley RJ; National Institute of Allergy and Infectious Diseases Collaborative Antiviral Study Group. Diagnosis of herpes simplex encephalitis: application of polymerase chain reaction to cerebrospinal fluid from brain-biopsied patients and correlation with disease. *J Infect Dis*. 1995;171(4):857–863.

36. De Tiège X, Héron B, Lebon P, Ponsot G, Rozenberg F. Limits of early diagnosis of herpes simplex encephalitis in children: a retrospective study of 38 cases. *Clin Infect Dis*. 2003;36(10):1335–1339.
37. Weil AA, Glaser CA, Amad Z, Forghani B. Patients with suspected herpes simplex encephalitis: rethinking an initial negative polymerase chain reaction result. *Clin Infect Dis*. 2002;34(8):1154–1157.
38. De Tiege X, Rozenberg F, Burlot K, Gaudelus J, Ponsot G, Heron B. Herpes simplex encephalitis: diagnostic problems and late relapse. *Dev Med Child Neurol*. 2006;48(1):60–63.
39. Levitz RE. Herpes simplex encephalitis: a review. *Heart Lung*. 1998;27(3):209–212.
40. Zimmerman RD, Russell EJ, Leeds NE, Kaufman D. CT in the early diagnosis of herpes simplex encephalitis. *AJR Am J Roentgenol*. 1980;134(1):61–66.
41. Schlesinger Y, Buller RS, Brunstrom JE, Moran CJ, Storch GA. Expanded spectrum of herpes simplex encephalitis in childhood. *J Pediatr*. 1995;126(2):234–241.
42. Kennedy PGE, Chaudhuri A. Herpes simplex encephalitis. *J Neurol Neurosurg Psychiatry*. 2002;73(3):237–238.
43. Greenberg SB, Taber L, Septimus E, Kohl S, Puck J, Bryan RN. Computerized tomography in brain biopsy-proven herpes simplex encephalitis. Early normal results. *Arch Neurol*. 1981;38(1):58–59.
44. Baskin H, Hedlund G. Neuroimaging of herpesvirus infections in children. *Pediatr Radiol*. 2007;37:949–963.
45. Davis LE. Diagnosis and treatment of acute encephalitis. *Neurologist*. 2000;6(3):145–159.
46. Roos KL. Encephalitis. *Neurol Clin*. 1999;17(4):813–833.
47. Lee CKK, Tschudy MM, Arcara KM. Drug doses. In Tschudy MM, Arcara KM, eds. *The Harriet Lane Handbook of Pediatrics: A Manual for Pediatrics House Officers*. 19th ed. Philadelphia, PA: Mosby; 2011:685–686.
48. Ward KN, Ohrling A, Bryant NJ, Bowley JS, Ross EM, Verity CM. Herpes simplex serious neurological disease in young children: incidence and long-term outcome. *Arch Dis Child*. 2012;97(2):162–165.
49. Gnann JW, Salvaggio MR. Drugs for herpesvirus infections. In: Cohen J, Powderly WG, eds. *Infectious Diseases*. 2nd ed. London, UK: Mosby; 2004:1895–1909.

**Nothing Is Simple About a Complex Febrile Seizure: Looking Beyond Fever as a Cause for Seizures in Children**

Sheila M. Hofert and Michael G. Burke

*Hospital Pediatrics* 2014;4;181

DOI: 10.1542/hpeds.2013-0098

<b>Updated Information &amp; Services</b>	including high resolution figures, can be found at: <a href="http://hosppeds.aappublications.org/content/4/3/181">http://hosppeds.aappublications.org/content/4/3/181</a>
<b>References</b>	This article cites 46 articles, 12 of which you can access for free at: <a href="http://hosppeds.aappublications.org/content/4/3/181.full#ref-list-1">http://hosppeds.aappublications.org/content/4/3/181.full#ref-list-1</a>
<b>Permissions &amp; Licensing</b>	Information about reproducing this article in parts (figures, tables) or in its entirety can be found online at: <a href="https://shop.aap.org/licensing-permissions/">https://shop.aap.org/licensing-permissions/</a>
<b>Reprints</b>	Information about ordering reprints can be found online: <a href="http://classic.hosppeds.aappublications.org/content/reprints">http://classic.hosppeds.aappublications.org/content/reprints</a>



**Nothing Is Simple About a Complex Febrile Seizure: Looking Beyond Fever as a Cause for Seizures in Children**

Sheila M. Hofert and Michael G. Burke

*Hospital Pediatrics* 2014;4;181

DOI: 10.1542/hpeds.2013-0098

The online version of this article, along with updated information and services, is located on the World Wide Web at:

<http://hosppeds.aappublications.org/content/4/3/181>

Hospital Pediatrics is the official journal of the American Academy of Pediatrics. A monthly publication, it has been published continuously since 2012. Hospital Pediatrics is owned, published, and trademarked by the American Academy of Pediatrics, 345 Park Avenue, Itasca, Illinois, 60143. Copyright © 2014 by the American Academy of Pediatrics. All rights reserved. Print ISSN: 2154-1663.

American Academy of Pediatrics

DEDICATED TO THE HEALTH OF ALL CHILDREN™

